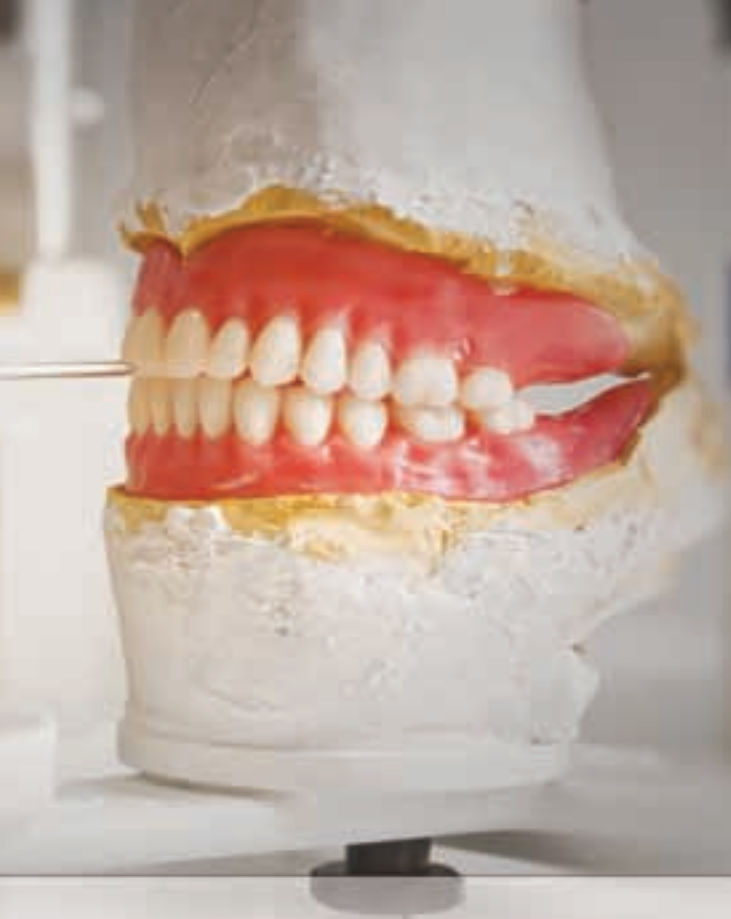

Removable Smile Design: The Core to Full-mouth Reconstructions



by John Nosti, DMD, FAGD, FACE

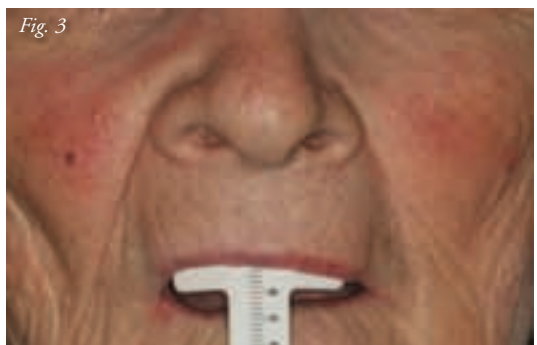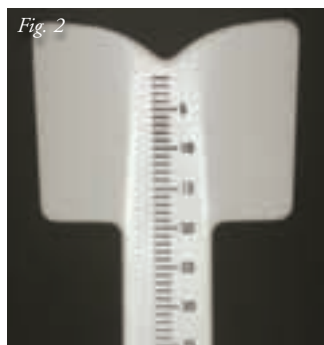
The year was 1996; it was my sophomore year in dental school and the administration took away a portion of our removable education in favor of hands-on education in oral implantology. The reason for the change in curriculum was that complete edentulism was falling in statistics nationwide with more patients holding on to their teeth longer. It was even stated by a few professors that traditional full dentures would eventually be a lost art form, and no longer needed. It is currently estimated that 10 percent of the U.S. population is edentulous.¹ This number is expected to grow due to the amount of aging adults in the United States. Likewise the effect of the economic downturn and illicit drug use has not been taken into consideration.

From 1996 to 2005, the amount of methamphetamine users doubled on average in the United States² and in some states that number quadrupled. In 2003, it was estimated that six percent of the U.S. population was using methamphetamines.³ In 2010, while some sources indicate the population using illicit drugs

has decreased; those same sources indicate the users requiring specialized treatment for a drug abuse problem increased.

No matter how you look at it, dentures will continue to be an essential part of dentistry. Many practitioners shy away from removable prosthetics due to the variability of procedures throughout the fabrication process resulting in an unpredictable outcome. I have spoken with many doctors who favor traditional fixed smile design over removable smile design. I will challenge, that in order to become proficient in fixed smile designs and full-mouth reconstructions, one must become proficient in removable prosthetic “reconstructions.” With the addition of some simple tools to your armamentarium, removable dentures will be an enjoyable and profitable process that can add to your cosmetic dentistry portfolio.

Figure 1 shows the Smile Design Kit by Ivoclar. The Papillameter (Figs. 2 & 3) is used to measure the maxillary lip length by using the fixed landmark of the incisive papilla. By



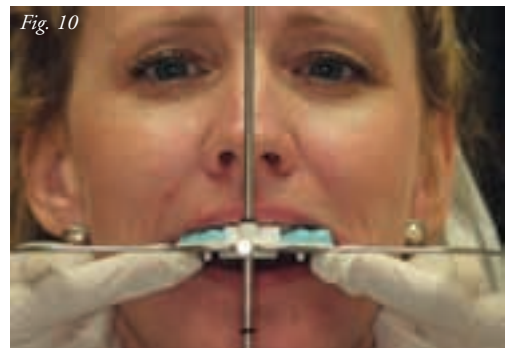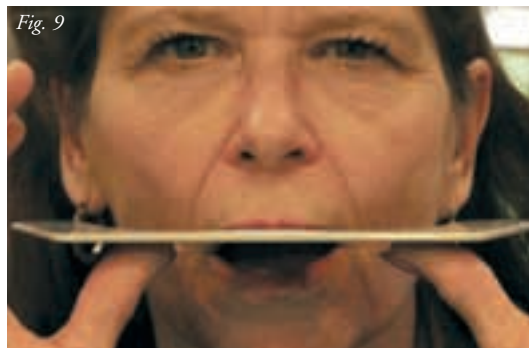determining the length between the maxillary lip at rest and the incisive papillae, the lab has an exact measurement to construct the wax rim or placement of the incisal edge in the wax setup. Transferring this information to the lab when ordering baseplates and wax rims allows the lab to custom make the wax rims and facilitates a faster secondary appointment for wax relations. The doctor is not left “eye balling” the ideal incisal edge position and wasting time cutting down a stock wax rim that is 6mm too long; or worse having to add wax because the rim is too short. Once the incisal edge position has been located, it can become much easier to focus on recording the proper midline and high smile line.

The Wax Rim Former (Fig. 4) is designed to facilitate the development of the occlusal plane once the desired incisal edge position has been achieved. Ensuring parallelism between the maxillary and mandibular rims is essential for a correct bite registration. When aligning the rims to Campers plane it is particularly important to be able to melt the rims uniformly. The ledge of the rim former fits precisely into the hamular notches on the maxillary cast. The hamular notches are always parallel to one another and to the midlevel of the face;^{4,5} it is important to have your base plate impressions detailed enough and free of distortion in these areas. The 5mm ledge present on the rim former ensures that when the maxillary wax rim is melted down to the desired incisal edge position (chosen by using the papillameter and marked on the wax rim), the occlusal plane will be uniform on both right and left side, and should be parallel to Campers plane. This

process saves a great deal of chair time and allows the dentist to be more proficient.

The wax rim former can be used in conjunction with the Alma gauge (dental gauge) (Fig. 5). This gauge allows you to measure both vertical (Fig. 6) and horizontal (Fig. 7) position of the maxillary anteriors from the incisive papillae on an existing denture or base plate. The average patient’s incisal edge is approximately 8-10mm facial from the incisive papillae.^{6,7,8} This allows you to measure the facial extension of the denture rim from the incisive papillae and make any corrections from both a visual confirmation with the patient, and a standard approach chairside. If the patient has an existing set of dentures that he or she would like duplicated, the arch form can be traced on the plastic sleeve (Fig. 8) of the Alma gauge and sent to the lab so that duplication of the arch form can be achieved. The vertical position of the incisors can also be recorded on the plastic sleeve so that the lab knows the precise horizontal and vertical position of the incisors.

The bite plane (Fig. 9) is used to confirm a proper occlusal plane by using the interpupillary line and Campers plane (the ala-tragus line). By determining the correct incisal edge position with help of the papillameter, rim former and bite plane, the facebow transfer in dentures becomes less important considering that the wax rim has been perfected to the proper occlusal plane and incisal edge position. For those wanting to use a facebow transfer, the Kois Earless Facebow (Fig. 10) can be utilized once the desired incisal edge position has been achieved. The Kois Earless Facebow is an excellent tool in communicating and



continued on page 82

transfer of the maxillary model to the lab for mounting on either the Panadent or Stratos articulator. This facebow utilizes a removable mounting plate to record the facial-incisal edge position of the maxillary central incisors. The average position of the maxillary central incisor is approximately 100mm from the condylar axis. There is a vertical component to the facebow to achieve the facial midline, as well as a horizontal component to match the interpupillary line and horizontal plane. Once your wax rim has been set to the ideal incisal position, this facebow can now be utilized.

Taking the bite relationship and setting up the occlusion on complete dentures is probably the single most important step in denture construction. Over the years I have consulted with many patients who were complaining that their brand new dentures, constructed in other offices, were ill-fitting. Many times the only treatment rendered to these patients was to equilibrate their dentures and correct the improper occlusion. The ideal way to record a centric bite registration is with a needle-point tracing technique. I have found the Gnathometer-M by Ivoclar to be useful in that it allows for both chairside bite registration technique and functional impression taking if desired. In basic terms, the Gnathometer consists of a marking pin that fits over the lower rim and opposes a striking plate that is fixed to the maxillary rim. The marking pin is adjustable, which allows for changes to the vertical dimension. The Gnathometer is mounted to base trays in the laboratory and returned for the same visit with the wax rims. Once the vertical dimension has been set with the wax rims, the bite registration can be completed. If desired, the functional impression can be completed on the base trays followed by the bite registration. The vertical dimension on the Gnathometer is adjusted until it is the same as was established with the wax rims. Once this is completed, the striking plate is marked with black marker, occlude spray or wax color (China Marker). The patient is instructed to move the mandible into protrusive, backward, followed by left and right lateral excursions (repeat process). The marking screw contacts the opposing plate, resulting in an arrow formed on the marking plate. The point of the arrow is equivalent to centric relation. A fixation device is placed over the point of the arrow and the upper and lower elements can be fixed together with bite registration material.

The cosmetic outcome of your denture is highly reliant on tooth selection and custom processing of the denture base by your laboratory. Depending on your case fee several denture tooth options present themselves from basic to premium in aesthetics and function. Both the Blue Line and PHONARES by Ivoclar are two excellent options in the premium and ultra premium range. Tooth selection is facilitated by the interala distance as measured by the Facial Meter (Fig. 11). Teeth are offered in small, medium or large molds with

choice of bold or soft forms, each offered in long or short for age appropriation.⁹

When restoring a fixed full-mouth rehabilitation the standard of care is to always work out the aesthetics, occlusion, function, etc. in temporaries. The thought of preparing rehabilitation and inserting a mouth full of ceramics without utilizing temporaries is absurd. So, why then do we do our removable reconstructions without temporaries?

Are you tired of seeing your patient for 20 post-op adjustments after the denture has been completed and “searching” for their sore spots? Have patients ever returned unhappy with the aesthetics of the denture after they are processed and after they have approved them at the wax try-in visit? I would strongly consider your first option of fabricating a diagnostic denture and utilizing a functional impression technique followed by a final denture fabrication. This two-denture process will allow you to make any changes to the aesthetics because the patient is allowed to “try out their smile,” rather than approving their smile during a 10-minute wax try-in appointment. The recoding of the functional impression over a period of time allows you to capture the patient’s musculature in motion and function, rather than relying on a single static impression completed in office.

The second option is to utilize the functional impression technique in your fabricated denture and relin once the kinks

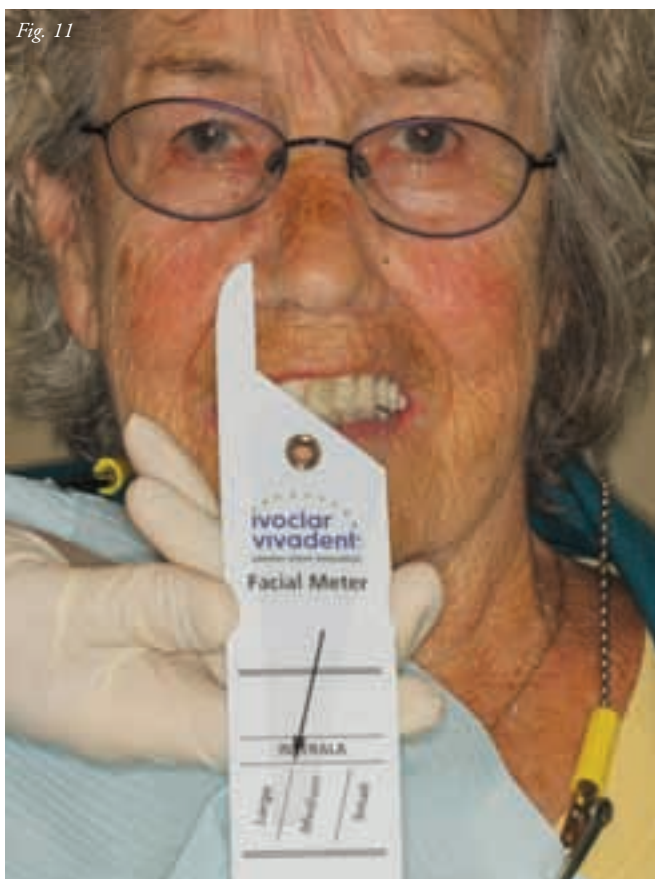

Fig. 11

are worked out. When the patient returns for scheduled post-op visits, the denture acrylic will bleed through the functional impression material where adjustments are necessary. Many times your scheduled adjustment visits are prior to the surfacing of sore spots on the patient. This secondary option relies more on the occlusion being correct at insert and will most likely require further equilibration due to the potential increase in vertical caused by the relin.

Whether your reconstructions are removable or fixed, having a step-by-step process and the correct tools allow you to be more proficient, predictable and profitable. With the elimination of unpredictability the process of denture fabrication becomes a more enjoyable experience for both the patient and practitioner. With the aging population increasing in the United States, and the expected increase in edentulism, higher demands will be made for high quality removable prosthetics. Some of the most dramatic "cosmetic makeover" patients, and most appreciative are those who have undergone removal prosthetic treatment. ■

References:

1. Summary Health Statistics for U.S. Adults: National Health Interview Survey, 2009, tables 11, 12. U.S. Department of Health and Human Services.
2. US Department of Health and Human Services, Substance Abuse and Mental Health Services Administration. 2005 national survey on drug use and health.
3. U.S. Department of Health and Human Services, Substance Abuse And Mental Health Services Administration, Office of Applied Studies. 2003 national survey on drug use and health.

4. *J Prosthodont.* 2008 Oct;17(7):572-5. Epub 2008 Aug 26. Occlusal plane orientation: a statistical and clinical analysis in different clinical situations. Jayachandran S, Ramachandran CR, Varghese R
5. *J Oral Rehabil.* 2007 Feb;34(2):136-40. Three-dimensional analysis of the occlusal plane related to the hamular-incisive-papilla occlusal plane in young adults. Fu PS, Hung CC, Hong JM, Wang JC.
6. *J Prosthet Dent.* 2009 Sep;102(3):194-6. Incisive papilla line as a guide to predict maxillary anterior tooth display. Oh WS, Hansen C.
7. *J Prosthet Dent.* 2007 Oct;98(4):312-8. The three-dimensional relationship on a virtual model between the maxillary anterior teeth and incisive papilla. Park YS, Lee SP, Paik KS.
8. *J Indian Dent Assoc.* 1984 Nov;56(11):425-8. An investigation into the distance between incisive papilla and incisal edge of maxillary central incisor. Kharat DU, Madan RS.
9. *J Ayub Med Coll Abbottabad.* 2009 Oct-Dec;21(4):125-8. Comparison of distance between maxillary central incisors and incisive papilla in dentate individuals with different arch forms. Zia M, Azad AA, Ahmed S.


Author's Bio

Dr. John Nosti practices full time in Mays Landing and Somers Point, New Jersey, with an emphasis on functional cosmetics, full mouth rehabilitations, and TMJ dysfunction. Dr. Nosti's down-to-earth approach and ability to demystify occlusion and all-ceramic dentistry has earned him distinction among his peers. He is privileged to instruct and mentor live patient and hands on programs with the Clinical Mastery Series and Dr. David Hornbook. He has lectured nationally on occlusion, rehabilitations and technology. He is a member of the American Dental Association, American Academy of Cosmetic Dentistry and American Academy of Craniofacial Pain. Dr. Nosti also holds fellowships in the Academy of General Dentistry and the Academy of Comprehensive Esthetics.



From Apnea to Zirconia

Find the CE you need on Dentaltown.com




View these recently added courses:

The Multi-Component Restoration: A Paradigm Shift in the Conservative Treatment of Root Caries
Speaker: Dr. Randall Cohen
Sponsor: Kuraray

Legitimate Early Orthodontics
Speaker: Dr. Wavel Wells
Sponsor: Blue Star Dental

ADA CERP Continuing Education Recognition Program

Farran Media is an ADA CERP Recognized provider. ADA CERP is a service of the American Dental Association to assist dental professionals in identifying quality providers of continuing dental education. ADA CERP does not approve or endorse individual courses or instructors, nor does it imply acceptance of credit hours by boards of dentistry.



Approved PACE Program Provider
FAGD/MAGD Credit
Approval does not imply acceptance by a state or provincial board of dentistry or AGD endorsement.
12/01/2004 to 12/31/2012

dentaltown
continuing education

